

# Leydig Cell Hyperplasia Revealed by Gynecomastia

Mohamed Fadl Tazi, MD, Soufiane Mellas, MD, Mohamed Jamal El Fassi, PhD,  
Moulay Hassan Farih, PhD

Service d'Urologie, CHU Hassan II, Fès, Morocco

*Leydig cell tumors are rare and represent 1% to 3% of all tumors of the testis. Leydig cell tumors affect males at any age, but there are 2 peak periods of incidence: between 5 and 10 years and between 25 and 35 years. Their main clinical presentation is a testicular mass associated with endocrinal manifestations that are variable according to age and appearance of the tumor. Our patient, a 17-year-old adolescent, presented with an isolated and painless hypertrophy of the right mammary gland. Clinical examination found gynecomastia and no testicular mass. Hormonal levels and tumor markers were normal. Testicular sonography showed an ovular and homogeneous right intratesticular mass 6 mm in diameter. We treated the patient with an inguinal right orchidectomy. The anatomopathological study found a nodule of Leydig cell hyperplasia. The patient recovered without recurrence at 8-month follow-up. The patient opted for mammoplasty 2 months after his orchidectomy rather than wait for the spontaneous gradual regression of his gynecomastia, which requires at least 1 year. Leydig cell hyperplasia manifests in the adult by signs of hypogonadism, most frequently gynecomastia. Although many teams prefer total orchidectomy because of the diagnostic difficulty associated with malignant forms, simple subcapsular orchidectomy should become the first-line treatment, provided it be subsequently followed by close surveillance, as it preserves maximum fertility, and these tumors usually resolve favorably.*

[Rev Urol. 2008;10(2):164-167]

© 2008 MedReviews, LLC

**Key words:** Testicular tumor • Leydig cell hyperplasia • Nonseminomatous germ cell tumors • Gynecomastia • Fertility

**T**he incidence of testicular tumors is low in the general population (2/100,000 men). The majority of these tumors originate germinally (92%), whereas others derive from interstitial cells (Leydig cells, Sertoli cells).<sup>1,2</sup>

Leydig cell tumors are rare and represent 1% to 3% of all tumors of the testis; nevertheless, they become more frequent with the increasing use of exploratory procedures in the diagnosis of sexual, fertility, and endocrinal troubles in adults.

Leydig cell tumors affect males at any age with 2 peaks of incidence: between 5 and 10 years and between 25 and 35 years.<sup>3,4</sup> The tumors present with a testicular mass associated with endocrinal manifestations that are variable according to the age at appearance of the tumor. In young, prepubescent patients, signs of premature virilization are frequently observed, and are associated in 10% of cases with gynecomastia.<sup>1</sup> In adult patients, gynecomastia is found in 20% to 40% of the cases, and is sometimes associated with decreased libido and infertility.

The appearance of Leydig cell tumor or hyperplasia in puberty is an exceptional event, the diagnosis of which is often difficult because of the physiological events accompanying this phase of growth (the beginning of virilization and physiological gynecomastia). Leydig cell tumors require laboratory diagnosis when they present in a nonpalpable form. Choice of therapy depends on whether a tumor is benign or malignant.

## Observation

AS, a 17-year-old adolescent, presented with an isolated and painless hypertrophy of the right mammary gland (gynecomastia; Figure 1). The patient had no history of pathology or drug intake, and went through puberty at the age of 13. Clinical examination found no testicular mass, no tumoral syndrome (except for his gynecomastia), and no other signs of endocrinal syndrome.

Testicular sonography revealed an ovular, homogeneous, and echogenic right intratesticular mass 6 mm in diameter. Hormonal levels were normal: testosterone, 4 ng/mL (normal range, 3-10 ng/mL); estradiol, 51 pg/mL (normal range, 20-60 pg/mL); follicle-stimulating hormone (FSH), 7 mU/mL (normal, < 8 mU/mL); luteinizing hormone (LH), 5 mU/mL (normal,

< 5.8 mU/mL). Tumor markers were normal.

According to clinical and paraclinical results, the patient was treated with an inguinal right orchidectomy. The anatomopathological study found a nodule of Leydig cell hyperplasia (the nodule consisted of a large number of Leydig cells with normal aspect and rare seminiferous tubules con-

taining Sertoli cells), but no germ cells (Figure 2).

The patient recovered favorably and there was no recurrence at 8-month follow-up. The patient opted for mammoplasty 2 months after his orchidectomy rather than wait for the spontaneous gradual regression of his gynecomastia, which requires at least 1 year (Figure 3).

Figure 1. A 17-year-old adolescent presented with unilateral gynecomastia.

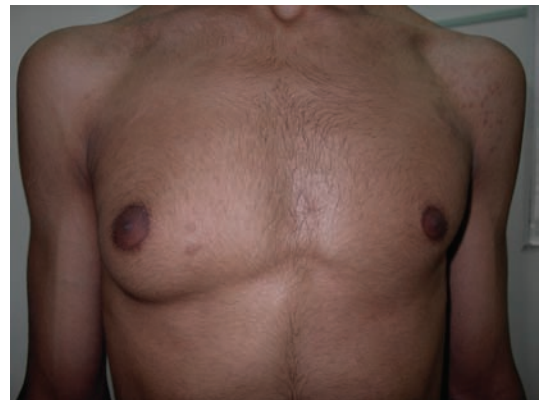

Figure 2. Interstitial widening by clusters and cords of hyperplastic cells of Leydig. Hematoxylin-eosin stain, original magnification,  $\times 100$ .

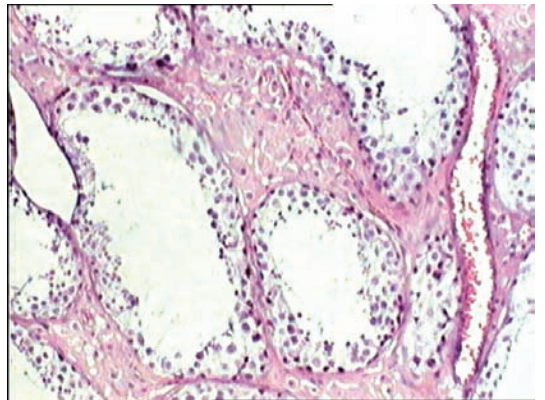
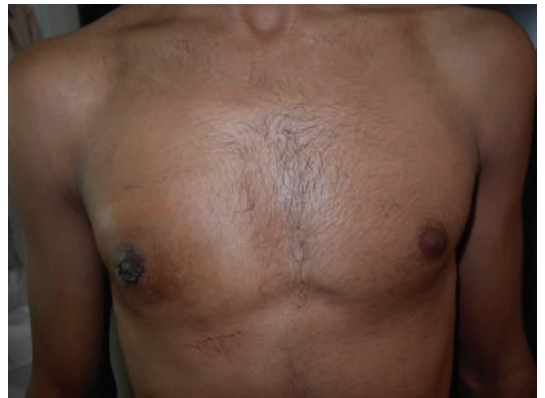

Figure 3. The same patient as in Figure 1 after mammoplasty.



## Discussion

In 1895, Sacchi reported the first case of Leydig cell tumor; currently the literature reports more than 250 cases.

In normal physiological conditions, Leydig cells situated in the peritubular spaces secrete testosterone under the influence of LH. The testosterone produced will have a paracrine role (diffusing the seminiferous tubules and uptake by Sertoli cells) and an endocrinal role (diffusing into the blood capillaries through peritubular spaces) and a small amount of the testosterone will be aromatized to estradiol at the Leydig cell.<sup>5</sup>

Leydig cell tumors and Leydig cell hyperplasia represent 3% of testicular tumors; however, the relative percentage of Leydig cell hyperplasia is difficult to determine. These tumors affect adults in 75% of cases (often between 25-35 years of age) and children in

normal or increased estradiol level, a very low testosterone/estradiol ratio (< 85), and a normal or lowered gonadotropin level. Leydig cell tumors and Leydig cell hyperplasia, compared with a normal Leydig cell, produce the testosterone, which is rapidly aromatized to estradiol because of increased aromatase activity.<sup>8</sup> There is normally a decline in the serum level of gonadotropin because of the negative biofeedback to the increase in estradiol; however, a normal level (our observation) or even an increased level of gonadotropin can be observed.<sup>9</sup>

Other tumors have endocrinal manifestations. Nonseminomatous germ cell tumors (NSGCT) of the testis produce human chorionic gonadotropin (hCG), so a tumor marker assay should be performed to rule out

the only therapeutic approach for rare bilateral tumors.<sup>10</sup>

Histologically, an increase in the number and in the size of the Leydig cells, which are often widened or have multiple nucleoli, defines this type of hyperplasia. Reinke crystalloids are rare and represent dedifferentiated cells, resembling their precursors.<sup>10</sup>

Leydig cell tumors are small volume tumors, consisting exclusively of Leydig cells, and must be distinguished from Leydig cell hyperplasia, which contain seminiferous tubules containing Sertoli cells.<sup>9</sup>

Although in some situations differentiating between Leydig cell tumors and Leydig cell hyperplasia is difficult, the most difficult diagnosis is that of malignant forms because tumoral necrosis, lymphatic or vascular invasion (75% of the cases),<sup>9</sup> cytonuclear atypia, number of mitoses, absence of well-defined edge or a capsule,<sup>7</sup> and aneuploidy on flow cytometry<sup>9</sup> are rarely present after surgical treatment. Follow-up is imperative to reveal retroperitoneal lymphadenopathy, or lung, osseous, or hepatic metastasis.<sup>9</sup> In adults, 10% to 15% of Leydig cell tumors are malignant, whereas no malignancies have been described in children.<sup>10</sup>

After orchidectomy, normalization of estradiol is expected in 24 to 48 hours, normalization of testosterone level within 10 days, normalization of spermatogenesis and gonadotrophin level within several months, and gynecomastia may require surgical treatment after 1 year because of its slow regression.<sup>9</sup>

## Conclusion

Hyperplasia of Leydig cells is rare, manifesting in the adult by signs of hypogonadism, mostly gynecomastia. The exploration of sexual disorders and fertility in men and advancements in sonography increase the possibility of diagnosing Leydig cell

---

*In adults...signs of hypogonadism are dominated by a unilateral or bilateral asymmetric gynecomastia, which could precede by some months to several years the appearance of the tumor; an erectile dysfunction often associated with decrease of libido; and infertility with oligo- or azoospermia.*

---

25% of cases (often between 5-10 years of age).<sup>6,7</sup>

In adults, because of activity in Leydig cell aromatase that transforms testosterone to estradiol, signs of hypogonadism are dominated by (a) a unilateral or bilateral asymmetric gynecomastia, which could precede by some months to several years the appearance of the tumor<sup>7</sup>; (b) an erectile dysfunction often associated with decrease of libido; and (c) infertility with oligo- or azoospermia. Palpation rarely reveals a painless hard testicular tumor. In children, on the other hand, the decreased or even absent aromatase activity of the Leydig cells manifests by premature pseudopuberty and androgen secretion.

Hormonal levels in adults reveal a normal or low testosterone level, a

testicular cancers before assuming an endocrinal syndrome.<sup>9</sup>

A scrotal ultrasound can also be used to diagnosis Leydig cell tumors and Leydig cell hyperplasia.<sup>10</sup> In 1989, Cooper described for the first time the ultrasound appearance of Leydig cell hyperplasia, which presents as an intratesticular round homogeneous mass from 2 to 6 mm in diameter.<sup>10</sup>

The treatment of Leydig cell tumors and Leydig cell hyperplasia is surgical, consisting of an inguinal orchidectomy and high ligation of the spermatic cord.<sup>10</sup> Because advancements in sonography techniques allow for better detection<sup>10</sup> and for increased specificity of the type of tumors, the present surgical tendency is conservative (enucleation, tumorectomy) with good results; it remains

hyperplasia and Leydig cell tumors. The main difficulty remains in the diagnosis of malignancies and the differentiation between Leydig cell hyperplasia and Leydig cell tumors, which can be imprecise. Therapeutic approaches differ if a Leydig cell hyperplasia is encountered; its benign pathology requires a conservative treatment. If a Leydig cell tumor is encountered, which can be malignant in 10% to 15% of cases, it may require a carcinological orchidectomy. ■

### References

1. Patrick-Dilworth J, Farrow GM, Oesterling JE. Non-germ cell tumors of testis. *Urology*. 1991;37:399-417.
2. Ciftci AO, Kologlu MB, Senocak ME, et al. Testicular tumors in children. *J Pediatr Surg*. 2001;36:1796-1801.
3. Thomas JC, Ross JH, Kay R. Stromal testis tumors in children: a report from the prepubertal testis tumor registry. *J Urol*. 2001;166:2338-2340.
4. Rich MA, Keating MA. Leydig cell tumors and tumors associated with congenital adrenal hyperplasia. *Urol Clin North Am*. 2000;27:519-528.
5. Bercovici JP, Kerlan V, Monguillou P, et al. Devenir à moyen et à long terme des tumeurs oestrogéniques à cellules de Leydig. *Ann Endocrinol (Paris)*. 1994;55:181-184.
6. Kim I, Young RH, Scully RE. Leydig cell tumors of the testis. *Am J Surg Pathol*. 1985;9:177-192.
7. Soriano Guilléna L, Pozo Romána J, Muñoz Calvoa MT, et al. Ginecomastia secundaria a tumor de células de Leydig. *An Esp Pediatr*. 2003;58(1):67-70.
8. Kuhn JM, Lefebvre H, Rieu M. Aspect endocrinien des tumeurs testiculaires. In: *Endocrinologie Masculine*. Paris: Editions Doin; 2003:299-313.
9. Kalfon A, Abram F, Kirsch-Noir F, et al. Les tumeurs testiculaires à cellules de Leydig. A propos de 10 observations. *Prog Urol*. 1999;9:299-304.
10. Piolat C, Dyon JF, Chavanis N, et al. Hyperplasie à cellules de Leydig du testicule chez l'enfant. *Prog Urol*. 2003;13:110-114.

### Main Points

- Hyperplasia of Leydig cells is rare, manifesting in the adult by signs of hypogonadism, mostly gynecomastia.
- Histologically, an increase in the number and in the size of the Leydig cells, which are often widened or have multiple nucleoli, defines this type of hyperplasia.
- The treatment of Leydig cell tumors and Leydig cell hyperplasia is surgical, consisting of an inguinal orchidectomy and high ligation of the spermatic cord.